

# HAND EXAM

a visual learning guide



# HAND EXAM

LOOK

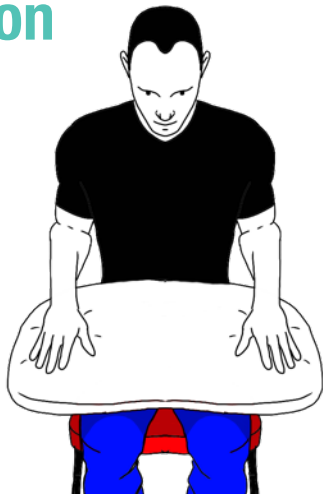FEEL

MOVE

SPECIAL TESTS

OTHER

## Position



Sat in chair

Bare from elbows down (watch off)

Hands on a pillow

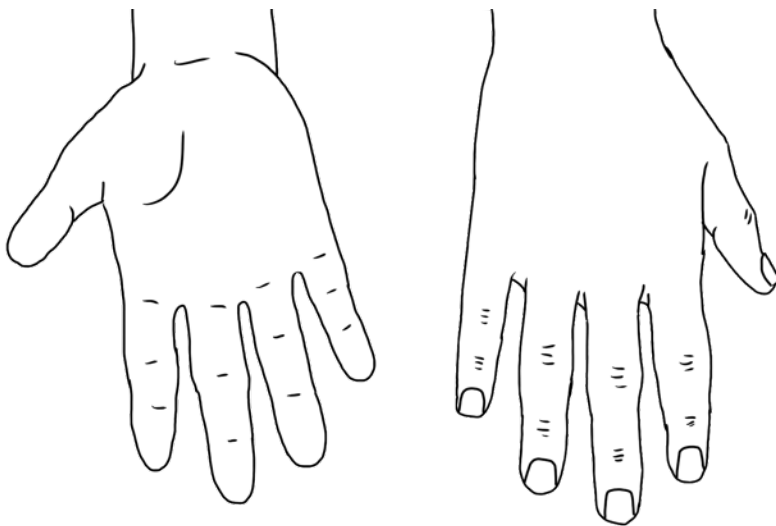
## Inspection

### WRISTS

Deformity - subluxation, deviation

Swelling - RA nodules, ganglion, gouty tophi

Scars - carpal tunnel release



### HANDS

Skin Changes - thinning or bruising (steroids)  
- palmar erythema (RA) - scars - wasting of  
1st dorsal interossei, thenar & hypothenar  
eminences

Swelling - Heberdens nodes (DIPJ - OA) -  
Bouchards nodes (PIPJ - OA) - boggy swelling  
(synovitis - RA) - trauma - cystic swelling  
(ganglion)

Deformity - Swan neck - Boutonniere's,  
Z-thumb - ulnar deviation - subluxation of  
MCPJs (all RA) - Dupuytren's contracture  
(various)

### NAILS

Pitting and onycholysis (psoriatic arthritis)

Nail fold infarcts (vasculitis)



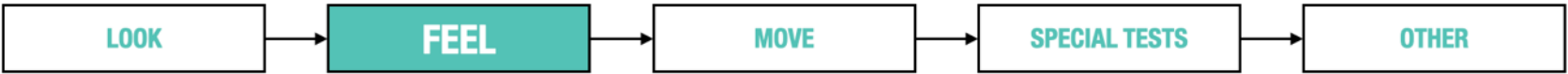### ELBOWS

Psoriatic rashes - also check behind ears

RA nodules

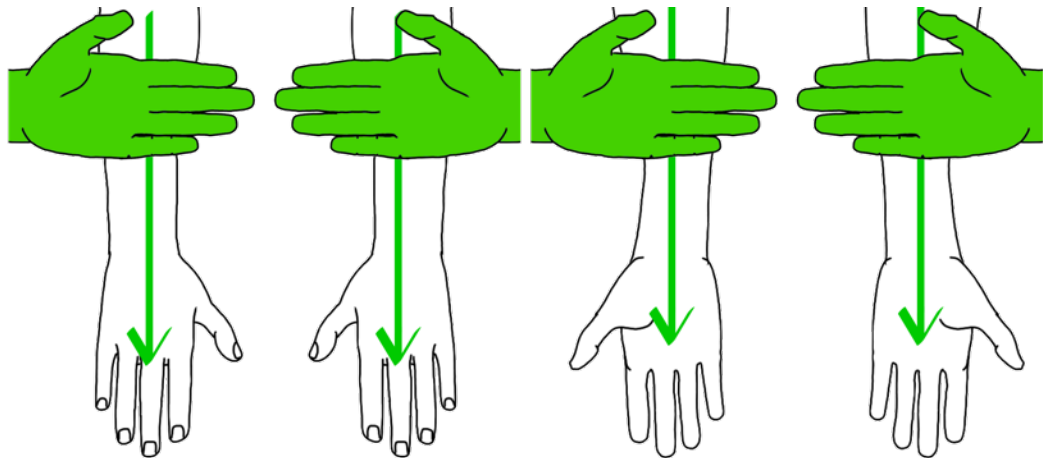
Gouty tophi

# HAND EXAM



## Temperature

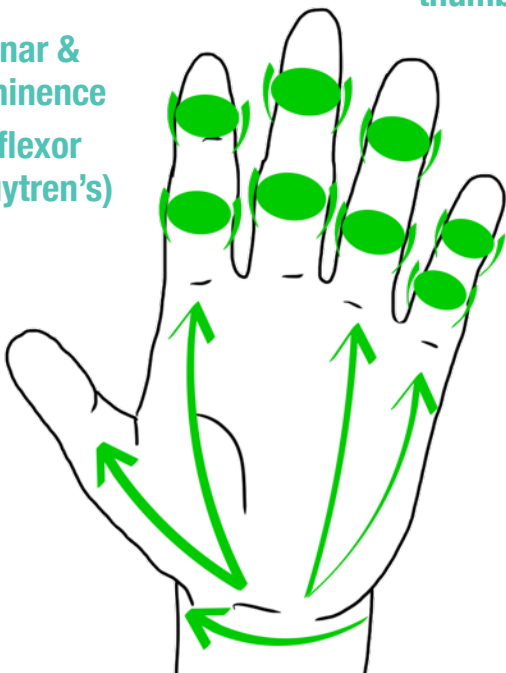
### BACK OF HANDS



## Palpation

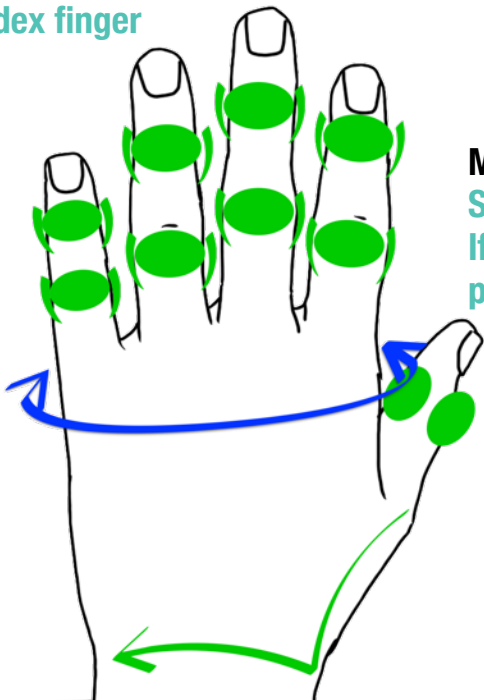
### HAND

Wasting of thenar & hypothenar eminence  
Thickening of flexor tendons (Dupuytren's)



### PIPJs, DIPJs & BASE OF THUMB

Bimanual palpation using thumb and index finger



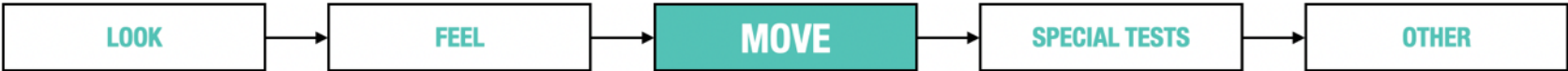### MCPJs

Squeeze gentle across row  
If painful then bimanual palpation of each MCPJ

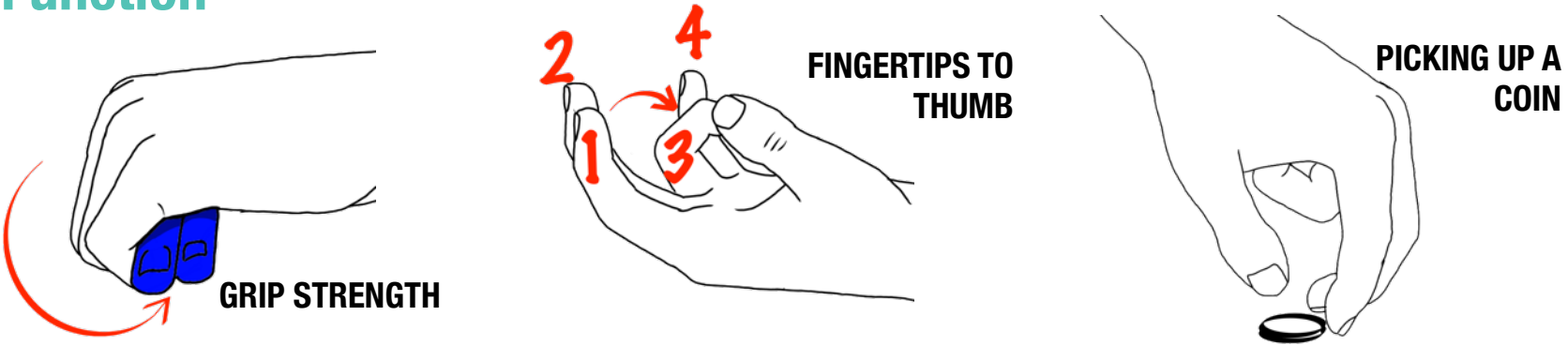
### WRIST

Ulnar border  
Ulnar head (extensor carpi ulnaris tendinitis - RA)  
Radial styloid process (?de Quervain's tenosynovitis)  
Anatomical snuff box for tenderness if trauma (# scaphoid)

**HAND EXAM**

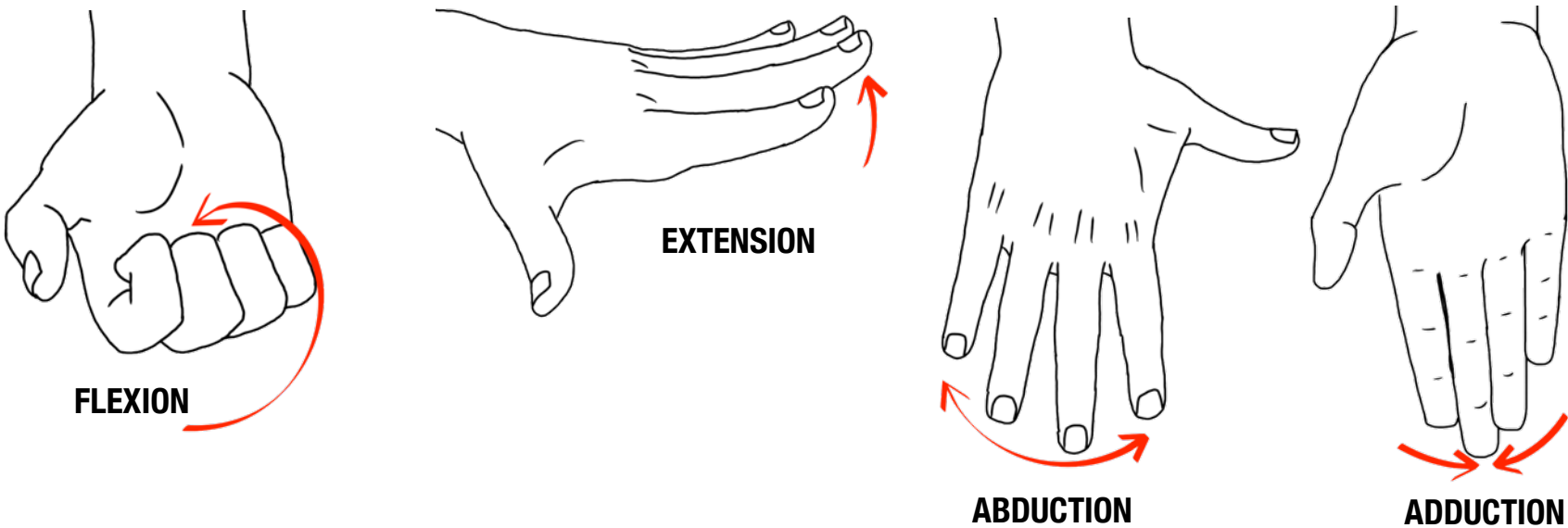


**Function**

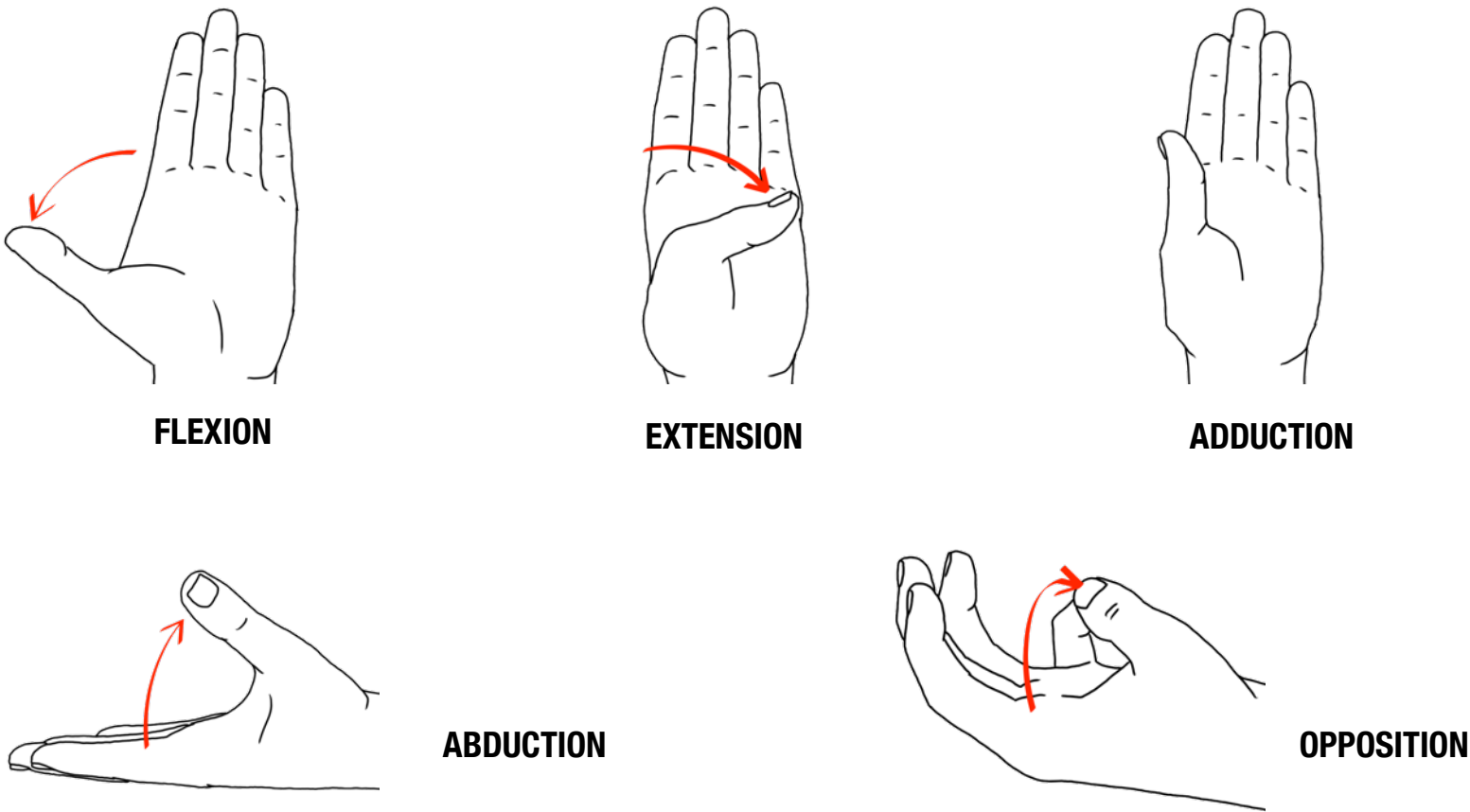


When examining an arthritic hand, function is more important than individual movements.

**Fingers**



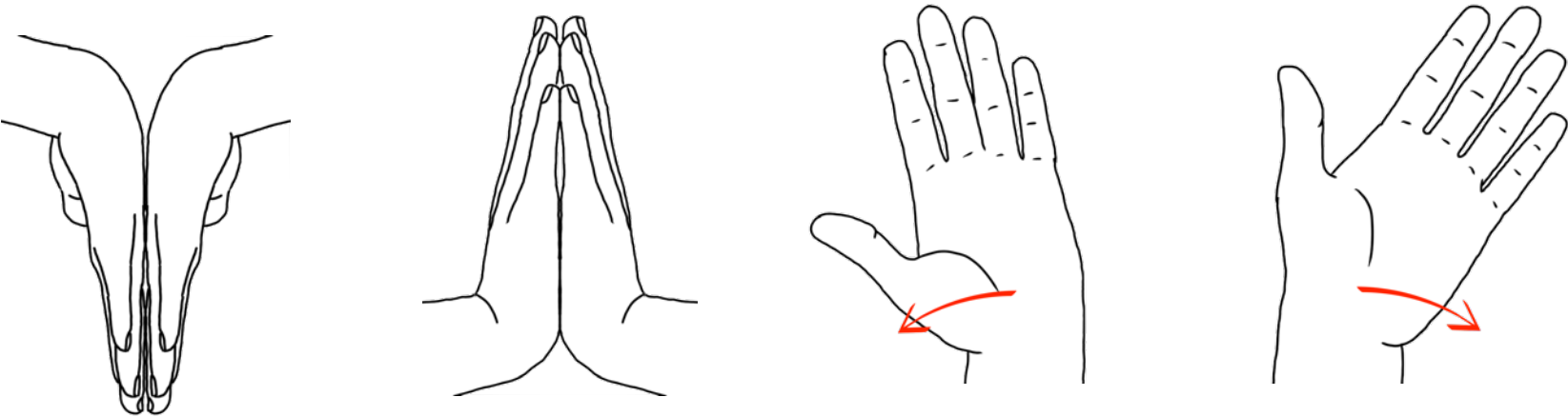
**Thumb**



HAND EXAM



Wrist



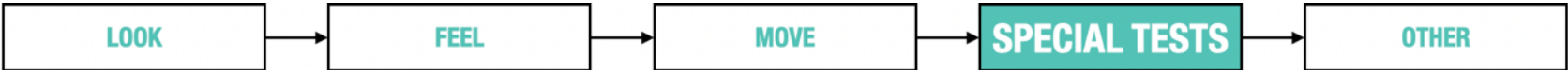FLEXION

EXTENSION

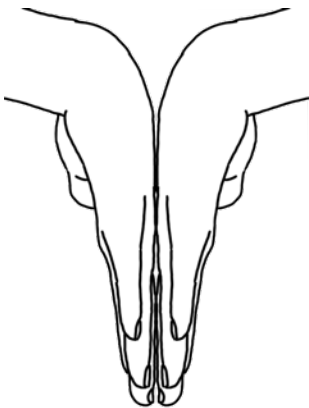
RADIAL & ULNAR DEVIATION

SUPINATION

PRONATION

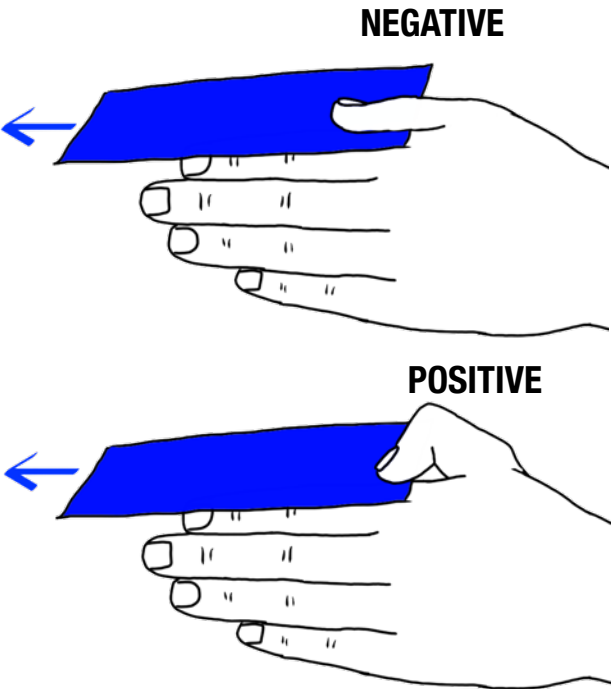


SPECIAL TESTS

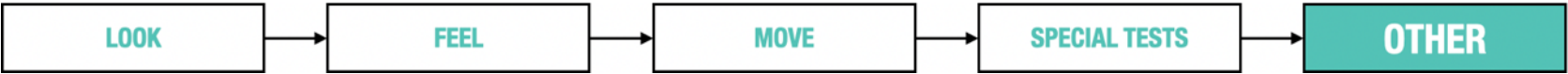

**PHALEN'S TEST  
FOR CARPAL TUNNEL SYNDROME**  
Ask patient to hold wrists in reverse prayer sign for up to 60sec.  
Positive if tingling in the distribution of the median nerve

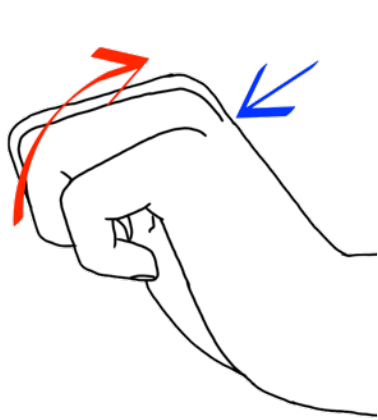
**FROMENT'S TEST  
FOR AN ULNAR NERVE PALSY**  
Ask patient to hold paper between a flat thumb and index finger & attempt to pull the paper out.  
The need for a pinch grip to hold the paper is a positive sign



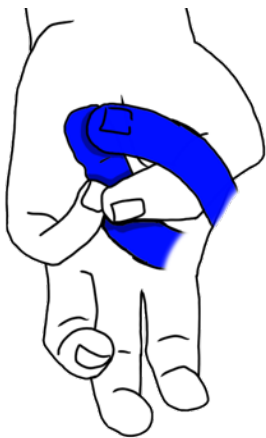HAND EXAM



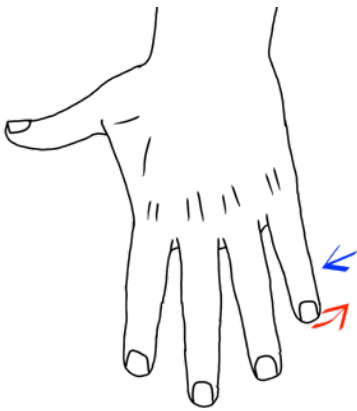
NEUROVASCULAR



**RADIAL - Power**  
Resisted wrist extension  
“Don’t let me push it down”

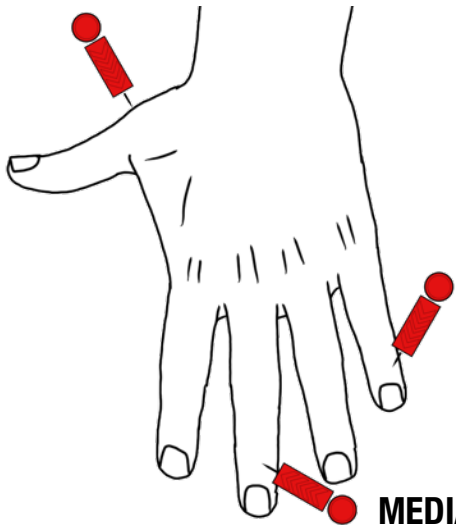


**MEDIAN - Power**  
Resisted thumb opposition  
“Put your thumb and your little finger together - don’t let me break them apart”



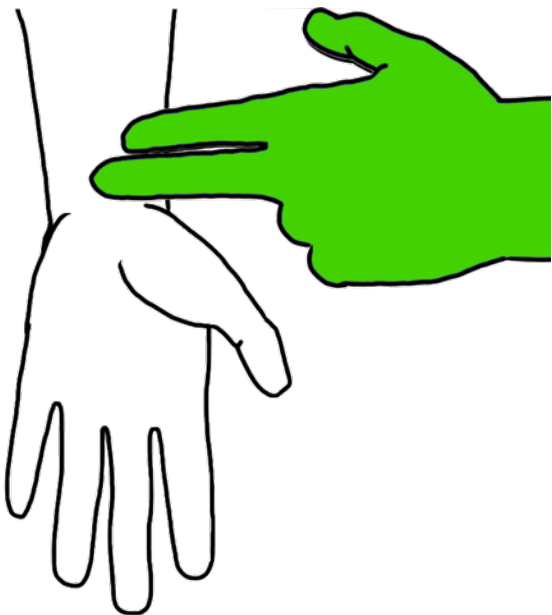
**ULNAR - Power**  
Resisted little finger abduction  
“Don’t let me push your finger in”

**RADIAL - Sensation**



**ULNAR - Sensation**

**MEDIAN - Sensation**



**VASCULAR**  
Capillary refill time  
Radial pulse  
Ulnar pulse (or Allen’s test)